

Nonsurgical Treatment of Varicocele

A Monograph

STEVEN JANNEY SMITH, M.D.,¹ and ROBERT I. WHITE, Jr., M.D.²

Abstract

Thousands of men in America undergo surgical correction of a varicocele annually. Varicocele embolization is a highly effective, non-surgical alternative that is a widely available, but underutilized technique in this country.

Introduction

Varicocele, the presence of varicose veins of the pampiniform plexus, has been the source of much controversy in the medical literature. It has been called the commonest correctable cause of male infertility, and is known to cause pain, and testicular atrophy in some patients. Tulloch first described surgical correction of varicocele in 1952 [1]. Now, almost 50 years later, open surgery is still the most common method of varicocele repair in the U.S.A., by a wide margin.

Varicocele embolization and sclerotherapy are newer, non-surgical methods of correcting varicocele[2,3]. These catheter-based techniques are performed by interventional radiologists, not urologic surgeons and have many advantages over open surgical treatment [4].

Pathophysiology of Varicocele

Approximately 10-15% of all men have varicoceles. Most are asymptomatic and many are not associated with infertility. Infertility is defined as no pregnancy after 1 year of unprotected intercourse. Among infertile couples, the incidence of varicocele increases to 30-40% [35,6].

Varicoceles most commonly occur on the left side of the scrotum due to absent or incompetent valves in the left internal spermatic vein (ISV), with subsequent reflux of blood down the vein when in the upright position. On physical exam, large varicoceles are visible, palpable, and increase in size with the Valsalva maneuver. Engorgement of the left pampiniform plexus and venous collaterals in the scrotum lead to elevated scrotal temperature and pressure causing hypoxia, oxidative stress and lower testosterone concentration in the testis [7,11,12]. It appears that varicocele may damage leydig cell function [8]. Other problems associated with varicocele include: increased resistance to blood flow, increased cadmium in the testis, increased DNA fragmentation, elevated mast cell concentration, elevated aquaporin S, abnormalities of the vas deferens and germ cell apoptosis leading to impaired spermatogenesis [7-10]. This may result in decreased sperm count, abnormal sperm motility and morphology [5,6,9]. The commonest semen abnormality in men with varicocele and infertility is poor sperm motility (less than 60% motile forms), followed by abnormal morphology, and to a lesser extent, depression of sperm count below the normal World Health Organization (WHO) value of 20 million/ml[5].

In adolescent boys, varicoceles are often discovered incidentally by a pediatrician or during a sports

¹Interventional Radiology, Adventist La Grange Memorial Hospital.

²Vascular Malformation Center, Yale School of Medicine, New Haven, Connecticut.

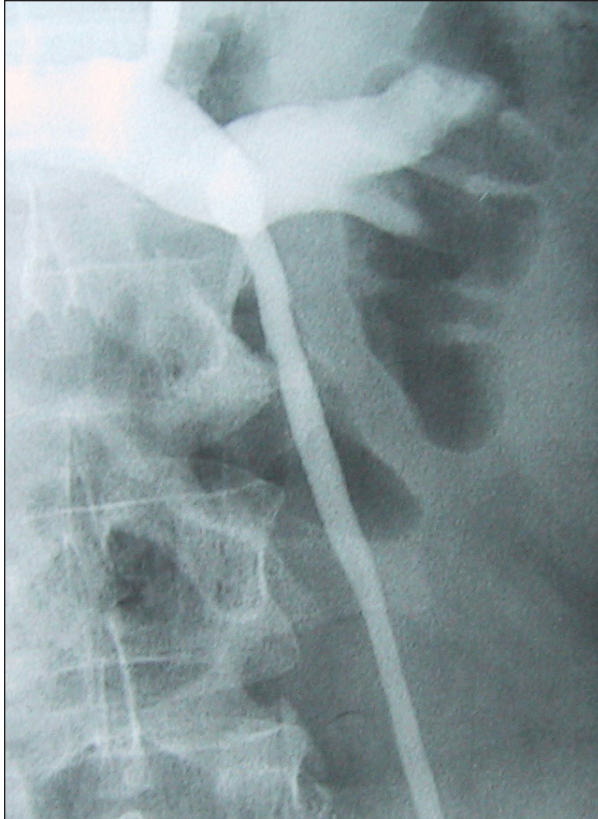


Figure 1a: Contrast injected via a catheter in the left renal vein refluxes down the internal spermatic vein (ISV).

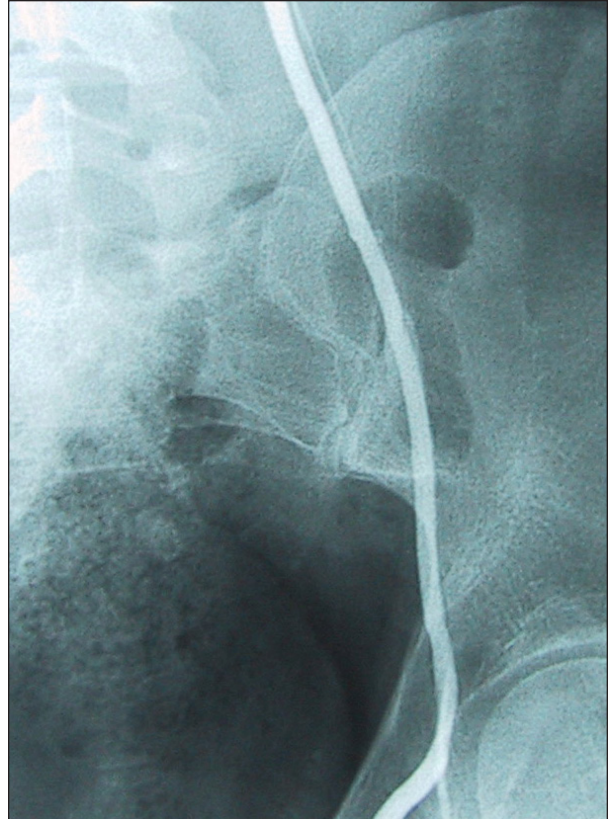


Figure 1b: Contrast injected into the upper ISV refluxes down into the scrotum indicating a varicocele.

physical. They may cause pain and testicular atrophy that is reversible after repair [13,14]. Adolescents with varicocele and more than 10-20% volume discrepancy between the testis on ultrasound or with elevated LH/FSH may have future subfertility and should be repaired [15,16,17]. Boys with very large varicoceles should probably be monitored for atrophy or hormonal changes, or repaired. Unfortunately, Pediatricians do not always examine for varicocele or refer patients for evaluation [18]. Adolescent varicoceles are easily and effectively treated non-surgically with embolization[13,19,20]. There is no evidence that all varicoceles in adolescent boy should be repaired, however.

Diagnosis of Varicocele

Large varicoceles are often visible on physical exam as a “bag of worms” appearance of the scrotum, especially in the upright position. The spermatic cord may be thickened on palpation. There are three clinical grades. Grade I is palpable only with Valsalva maneuver. Grade II, a moderate varicocele, is palpable without Valsalva and Grade III is a large varicocele that is visible without palpation [21].

High resolution and color flow Doppler ultrasound can be useful in evaluating varicocele patients. Accurate diagnosis of testicular atrophy is straightforward, and ultrasound can be used to detect smaller subclinical varicoceles [22-25]. Repair of these smaller varicoceles is controversial, but there is evidence that results of treatment are as good as the results of repair of clinical varicocele [23,26,27]. Other studies suggest that these smaller varicoceles are not significant [8]. Ultrasound can also be used to evaluate the success of varicocele repair.

Techniques of Varicocele Repair

Surgery

Surgical repair of a varicocele is usually performed as outpatient surgery under general anesthesia. An incision is made, and the ISV or its branches are located and ligated, to divert blood flow into other normal veins in the pelvis. The incision may be retroperitoneal (“high ligation”), inguinal, or sub-inguinal. Laparoscopic ligation of the ISV is not widely performed. Care must be taken to ligate all branches of the vein in order to avoid post surgical recurrence or persistence of the varicocele. After vein

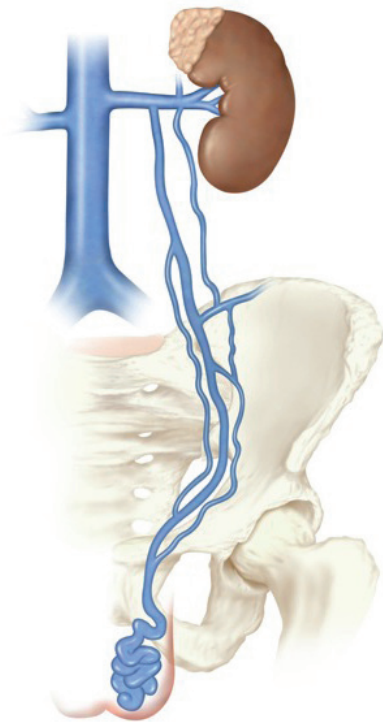


Figure 2a: The left internal spermatic vein allows reflux of blood down to the scrotum causing a varicocele.

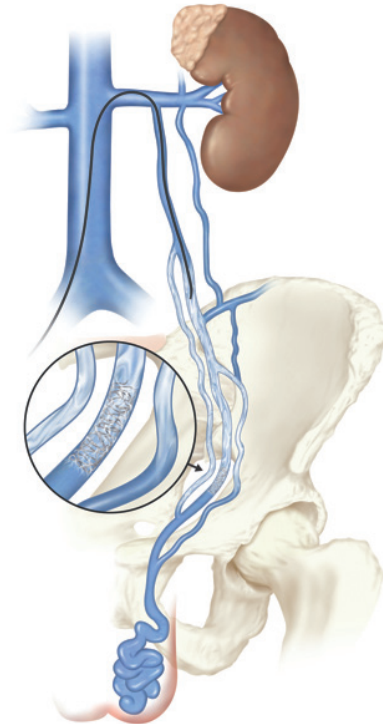


Figure 2b: A platinum coil, delivered through a catheter, is placed in the ISV near the internal inguinal ring, then a sclerosing agent is injected to block collateral veins. This helps to prevent recurrences.

ligation, the layers of the abdomen, or scrotum are sutured in standard fashion. The patient is recovered, and usually can go home later in the day. An average of 7% of patients may develop a hydrocele as a complication of varicocele surgery[29]. The most invasive form of surgery, sub-inguinal microsurgery involves cutting open the scrotum and pulling out the testis, but has a lower hydrocele rate and a higher success rate than other types of surgery[28].

Embolization

Varicocele embolization has been performed since the late 1970's [2]. It is an outpatient procedure, performed using mild IV sedation and local anesthesia [3,4,30]. A small angiographic catheter is introduced into the venous system either via the right femoral vein, the right jugular vein, or the basilic vein. The catheter is guided with the aid of fluoroscopy into the left renal vein (in the case of the more common left varicocele) and a contrast venogram is performed (Fig 1a, and 1b). A selective ISV venogram is then performed, and serves as a "road map" for embolizing the vein. The catheter is then maneuvered down the vein to the level of the internal inguinal ring. Usually the vein or its branches are then embolized by injecting steel or platinum spring-like embolization coils. The vein is blocked at the internal inguinal ring

level, at the sacroiliac joint level, then in the upper one-third of the vein. Often a liquid or foam sclerosing agent is injected to seal off tiny side branches [4,19] In effect the incompetent vein is "tied off" internally, accomplishing what the urologist does, but without invasive surgery [31,60]. In addition, the first set of coils placed at the internal inguinal ring allows the interventional radiologist to identify important collaterals. Only small amounts of sclerosant are required to occlude these collaterals(Fig. 2a, 2b). Right-sided varicoceles are embolized with the same basic technique. Radiation exposure to the gonads during the procedure is low, no more than that received during a chest radiograph[2].

Various liquid or foam sclerosing agents may also be injected (with caution) without use of metal coils ("sclerotherapy"), to successfully eliminate varicoceles [32,33]]. After embolization/sclerotherapy, a completion venogram is performed to insure that all branches of the ISV have been blocked, then the catheter is withdrawn (Fig 3). Manual pressure is applied to the puncture site for 10 minutes to achieve hemostasis. No sutures are used. The patient is observed for a few hours before discharge home. They may resume all normal activities in a day or two.

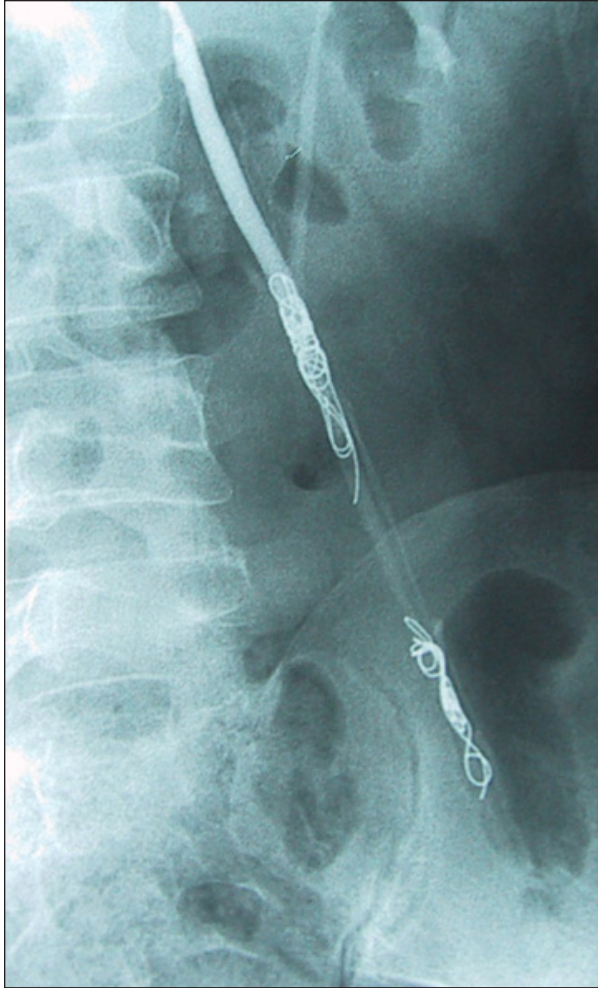

Figure 3: After embolization is complete the coils block flow into the varicocele. The patient's semen analysis returned to W.H.O. normal parameters, and his wife conceived a few months later.

Discussion: Controversies in Varicocele Management

It is well known that the swelling and pain associated with large varicoceles are reduced after varicocele repair [13,39]. The first controversy is whether varicocele is associated with male infertility. This is a difficult question to answer because many infertile couples are unwilling to submit themselves to randomized trials. It has been shown in multiple studies, however, that male partners of infertile couples do have an increased incidence of varicocele (20-40%) when compared with men in general, in whom the incidence of varicocele is no greater than 10-15%[40]. Nagao et al. showed that men with varicocele (whether infertile or not) had abnormal semen analysis and increased baseline gonadotropins on average when compared to normal fertile men. They

concluded that varicocele is associated with some degree of testicular dysfunction regardless of fertility status [41]. Varicocele may be associated with low serum testosterone and impotence [42]. Furthermore, the pernicious effects of varicocele may be progressive over time [43] and the condition is more strongly associated with secondary than primary infertility [44]. It is perplexing however that most men with varicocele are not infertile. It seems that varicocele, plus some other “co-factor” must be combining to produce subfertility [45].

The secondary controversy is linked to the first: does infertility improve after varicocele repair? Some studies have suggested there is no improvement [46,47]. A widely quoted meta-analysis in Cochrane Database concluded that there was no significant increase in fertility after varicocele repair. That analysis, unfortunately, included several poorly designed studies. When those are removed, it can be seen that the odds ratio for pregnancy after varicocele repair is almost three times that for no treatment [48,49]. The American Society for Reproductive Medicine advises varicocele treatment for male partners of couples trying to conceive when: the man has a palpable varicocele and an abnormal semen analysis, and the female has normal or correctable fertility [6]. Many other studies have shown a significant improvement in semen analysis and pregnancy rates after varicocele repair. A meta-analysis of 65 studies by Schlessinger et al.[5] found an average pregnancy rate of 37% in infertile couples in whom surgical varicocelectomy was performed. In a randomized trial, Laven et al. noted significant improvement in semen analysis in patients treated with embolization versus a control group. [50]. Serum testosterone has been shown to increase after varicocele repair [51,52].

Many infertile couples choose to skip varicocele treatment, due to uncertainty about it, and proceed straight to assisted reproductive technology (ART) procedures, like ICSI (which bypasses male factor infertility by injecting a sperm directly into the ovum). Still, there is evidence that varicocele repair may downstage the level of intervention needed to achieve pregnancy with these techniques [53-58]. Cost-effectiveness of varicocele repair is a hotly debated topic [9,59]. Varicocele repair may also improve fertility in the future for couples undergoing current ART treatments.

The third controversy, which seems to be resolving as more series are reported, is whether varicocele

embolization is as safe and effective as varicocele surgery. Reviewing seven studies that directly compare open surgery versus embolization, embolization was found to be equal to surgery in ultimate pregnancy rate. Significant improvement in semen analysis was equal in four studies, with one showing superiority of surgery, and one superiority of embolization. The recurrence rate of varicocele ranged from 2% to 11% for embolization and 0% to 45% for surgery [60-66]. One of the studies compared cost of surgery versus embolization and found them equivalent [65].

These studies also revealed some advantages of embolization over surgery. There was a general trend of lower morbidity with embolization overall. Dewire et al. and Feneley et al. analyzed the length of time until resumption of full activity after embolization versus surgery. They found an average of 2 days for complete recovery for embolization and 2-3 weeks for surgery [61,65]. Dewire found 24% of surgical ligation patients required overnight hospital stay, but no embolization patient did. All infections occurred in the surgery group, and one surgical patient lost a testis.

Other potential advantages of embolization vs. surgery include: no need for general anesthesia and no incisions, sutures, or reported infections. Also, bilateral varicoceles can be treated with embolization from a single femoral venipuncture, whereas surgery requires two separate incisions. Technical success for embolization is now high (95.7-100%) and recurrence very low[19,31]. A study currently in press will report greater than 97% final success and no complications for treatment via catheter in a very large cohort of patients.

Feneley et al. questioned patients who had undergone both surgical ligation and embolization as to preference. All preferred embolization [61].

Despite the greater safety and equivalence or superiority of embolization/ sclerotherapy vs. open surgery, it is likely that 90% of varicocele repair in the U.S. is still performed surgically. Dewire et al. informed patients of the option of choosing embolization versus surgery and noted that about half chose embolization [65]. From this we may conclude that most American men are not being informed about the option of varicocele embolization, although it is now widely available. If varicocele embolization or sclerotherapy is available, the literature supports it as the best first option for patients today. More invasive surgery can be reserved for the 2-3 % of patients who may require it.

Bibliography

1. Tulloch WS. Consideration of sterility factors in the light of subsequent pregnancies. Subfertility in male. *Edinburgh Med J* 1952; 59:29.
2. Walsh P, White R. Balloon Occlusion of the Internal Spermatic Vein for the Treatment of Varicoceles. *JAMA* 1981;246:1701-1702.
3. Halden W, White R. Outpatient Embolotherapy of Varicocele. *Urol Clin N Am* 1987;14:137-144.
4. Smith S, Sewall L. Treating varicoceles with embolization. *Endovascular Today*. 2009; April:57-60.
5. Schlessinger MH, Willets IF, Nagler HM. Treatment outcome after varicocelectomy. *Urol Clin North Am* 1994; 21:517-529.
6. Report on varicocele and infertility by the Practice committee of the American Society for Reproductive Medicine. *Fertil Steril* 2008;90:S247-9
7. Agarwal, A, Sharma R, Desai N, et al. Role of Oxidative Stress in Pathogenesis of Varicocele and Infertility *Urol* 2009; 73:461-469.
8. Kim H, Goldstein M. Adult Varicocele. *Curr Opin Urol* 2008; 18:608-612.
9. French D, Desai N, Agarwal A. Varicocele repair: does it still have a role in infertility treatment? *Curr Opin Obstet Gynecol* 2008; 20:269-274.
10. Benhoff S, Millan C, Hurley I, et al. Bilateral increased apoptosis and bilateral accumulation of cadmium in infertile men with left varicocele. *Hum Reprod* 2004;19(3):616-627.
11. Zorogniotti AW, Sealton AI: Studies in temperature, human semen quality and varicocele. *J. Reprod Steril* 1988; 82:563.
12. Lerchl A, Keck C, Spiteri-Grech S, Nieschlag E: Diurnal variations in scrotal temperatures of normal men and patients with varicocele before and after treatment. *Int J Androl* 1993;16:195.
13. Reyes BL, Trerotola SO, Venbrux AC, et al. Percutaneous embolotherapy of adolescent varicocele: Results and long-term follow-up. *J Vasc Interv Radiol* 1994;5:131.
14. Kass EJ, The Adolescent Varicocele: Treatment and Outcomes *Curr Urol Rep* 2002;3:100-106.
15. Guarino N, Tadini B, Bianchi M. The Adolescent Varicocele: the crucial role of Hormonal tests in Selecting patients with Testicular Dysfunction. *J Pediatr Surg* 2003;38: 120-123.
16. Diamond D, Zurakowski D, Baur S, et al. Relationship of Varicocele Grade and Testicular Hypotrophy to Semen Parameters in Adolescents. *J Urol* 2007;178:1584-1588.
17. Salzhauer E, Sokol A, Glassberg K. Paternity after Adolescent Varicocele Repair. *Pediatrics* 2004;114:1631-1633.
18. Kubal A, Nagler H, Zahalsky M et al. The adolescent Varicocele: Diagnosis and Treatment Patterns of Pediatricians. A Public Health Concern? *J Urol* 2004;171:411-413.
19. Reiner E, Pollak J, Henderson K, et al. Initial experience with 3% Sodium Tetradecyl Sulfate Foam

- and Fibred Coils for Management of Adolescent Varicocele. *J Vasc Interv Radiol* 2008; 19:207-210.
20. Alqatani A, Yazbeck S, Dubois J et al. Percutaneous Embolization of Varicoceles in Children: A Canadian Experience *J Ped Surg*. 2002;37:783-5
 21. LaNasa JA Jr, Lewis RW. Varicocele and its surgical management. *Urol Clin North Am* 1987;14:127-135.
 22. Behre HM, Nashan D, Nieschlag E. *International Journal of Andrology* 1989;12:395-403.
 23. McClure RD, Khoo, D, Jarvi K, Hricak H. Subclinical varicocele: The effectiveness of varicocelectomy. *Journal of Urology* 1991;145:789-791.
 24. Gonda RL Jr, Karo JJ, Forte RA, O'Donnell KT. Diagnosis of subclinical varicocele in infertility. *AJR* 1987;148:71-75.
 25. Petros JA, Andriole GL, Middleton WD, Picus DA. Correlation of testicular color doppler ultrasonography, physical examination and venography in the detection of left varicoceles in men with infertility. *Journal of Urology* 1991;145:785-788.
 26. Marsman JWP. Clinical versus subclinical varicocele: venographic findings and improvement of fertility after embolization. *Radiology* 1985;155:635-638.
 27. Marsman JWP, Schats R. The subclinical varicocele debate. *Human Reproduction* 1994;9:1-8.
 28. Marmar J, Kim Y. Subinguinal Microsurgical Varicocelectomy: a Technical Critique and Statistical analysis of Semen and Pregnancy data. *J Urol* 1994;152:1127.
 29. Szabo R, Kessler R. Hydrocele following Internal Spermatic Vein Ligation: a Retrospective Study and review of the Literature. *J Urol* 1984;132:924.
 30. Zuckerman AM, Mitchell SE, Venbrux AC, et al: Percutaneous varicocele occlusion: Long-term follow-up. *J Vasc Interv Radiol* 1994;5:315.
 31. Nabi G, Asterlings, Greene DR, et al. Percutaneous embolization of varicoceles: outcomes and correlation of semen improvement with pregnancy. *Urology*. 2004;63:359-363.
 32. Gandini R, Konda D, Reale CA, et al. Male varicocele: transcatheter foam sclerotherapy with sodium tetradecyl sulfate-outcome in 244 patients. *Radiology*. 2008;246:612-618.
 33. Gazzera C, Rampado O, Savio L, Et Al. Radiological Treatment of Male Varicocele; Technical, Clinical, Seminal, and Dosimetric Aspects. *La Radiologica Medica*, 2006; 111: 449-458.
 34. Richter EJ,, Zietler E, Seyfarth W. Phlebography and sclerotherapy of the spermatic veins. *Semin Interv Radiol* 1984;1:175.
 35. Kumpman W, Riedl P, Bliem J, et al. Cyanoacrylate in spermatic vein embolization. *Semin Interv Radiol* 1984;1:170.
 36. Sigmund G, Bahren W, Gall H, et al. Idiopathic varicoceles: Feasibility of percutaneous sclerotherapy. *Radiology* 1987;164:161.
 37. Thon WF, Gall H, Danz B, et al. Percutaneous sclerotherapy of idiopathic varicocele in childhood: A preliminary report. *J Urol* 1989;141:913.
 38. Hunter DW, King MJ, Aeppli DM, et al. Spermatic vein occlusion with hot contrast material: Angiographic results. *J Vasc Interv Radiol* 1991;2:507.
 39. Kass EJ, Reitelman C. Adolescent varicocele. *Urol Clin North Am* 1995;22:151-158.
 40. Pryor JL, Howards SS. Varicocele. *Urol Clin North Am* 1987;14:499-513.
 41. Nagao RR, Plymate SR, Berger RE, Perin EB, Paulsen CA. Comparison of gonadal function between fertile and infertile men with varicoceles. *Fert Steril* 1986;46:930-933.
 42. Younes A. Low Plasma Testosterone In Varicocele Patients With Impotence and Male Infertility. *Arch Androl* 2000; 45: 187-195.
 43. Johnson DE, Pohl DR, Rivera-Correa H, Varicocele: An Innocuous Condition? *World Health Organization, South Med J* 1970; 63:34.
 44. Gorelick J, Goldstien M, Loss of Fertility in Men with Varicocele. *Fertil Steril* 1993;59:613-616.
 45. Marmar J, The Pathophysiology of Varicoceles in the Light of Current Molecular and Genetic Information. *Hum Reprod Upd* 2001; 7:461-472.
 46. Vermeulen A, Vadeweghe M. Improved fertility after varicocele correction: fact or fiction? *Fertility and Sterility* 1984;42:249-256.
 47. Evers JH, Collins J, Clarke J. Surgery or Embolisation for Varicoceles in Subfertile Men. *Cochrane Database Syst Rev*. 2009; 1:CD000479.
 48. Ficarra V, Cerruto M, Liguori G, et al. Treatment of Varicocele in Subfertile Men: The Cochrane Review- A Contrary Opinion. *Euro Urol* 2006; 49:258-263.
 49. Marmar J, Agerwal A, Prabakaran S, et al. Reassessing the Value of Varicocelectomy as a Treatment for Male Subfertility with a New Meta-Analysis. *Fert Steril* 2007; 88:639-646.
 50. Laven JS, Haans LC, Mali WP, teVelde ER, Wensing CJ, Eimers JM. Effects on varicocele treatment in adolescents: a randomized study. *Fert Steril* 1992;58:756-762.
 51. Gat Y, Gornish M, Belenky A, et al. Elevation of Serum Testosterone and Free Testosterone after Embolization of the Internal Spermatic Vein for the Treatment of Varicocele in Infertile Men. *Hum Reprod* 2004;10:2303-2306.
 52. Cayan S, Kadioglu A, Orhan I, et al. The Effect of Microsurgical Varicocelectomy on Serum Follicle Stimulating Hormone, Testosterone and Free Testosterone Levels in Infertile Men with Varicocele. *BJU Inter* 1999; 84:1046-1049.
 53. Tanahatoo S, Maas WM, Hompes PG, et al. Influence of Varicocele Embolization on the Choice of Infertility Treatment. *Fert Steril* 2004; 6:1679-1683.
 54. Cayan S, Erdemir F, Ozbey I, et al. Can Varicocelectomy Significantly Change the Way Couples Use Assisted Reproductive Technologies? *J Urol* 2002; 167:1749-1752.
 55. Esteves SC, Glina S. Recovery of Spermatogenesis after Microsurgical Subinguinal Varicocele Repair in Azoospermic Men Based on Testicular Histology. *Int Braz J Urol* 2005; 31:541-548.
 56. Daitch JA, Bedaiwy MA, Pasqualotto EB, et al.

- Varicolectomy Improves Intrauterine Insemination Success Rates in Men with Varicocele. *J Urol* 2001; 165(5): 1510-1513.
57. Gat Y, Bachar G, Everaert K, et al. Induction of Spermatogenesis in Azoospermic Men after Internal Spermatic Vein Embolization for the Treatment of Varicocele. *Hum Reprod* 2005; 20(4):1013-1017.
 58. Boman JM, Libman J, Zini A. Microsurgical Varicolectomy for Isolated Asthenospermia. *J Urol* 2008; 180(5):2129-2132.
 59. Meng MV, Greene KL, Tureck PJ. Surgery or Assisted Reproduction? A Decision Analysis of Treatment Costs in Male Infertility. *J Urol* 2005; 174(5):1926-1931.
 60. Shlansky-Goldberg RD, VanArsdalen KN, Rutter, CM, Soulen MC, Haskal ZJ, Baum RA, Redd DC, Cope C, Pentecost MJ. Percutaneous varicocele embolization versus surgical ligation for the treatment of infertility: changes in seminal parameters and pregnancy outcomes. *JVIR* 1997;8:759-767.
 61. Feneley MR, Pal MK, Nockler IB, Hendry WF. Retrograde embolization and causes of failure in the primary treatment of varicocele. *British Journal of Urology* 1997;80:642-646.
 62. Sayfan J, Soffer Y, Orda R. Varicocele treatment: prospective randomized trial of 3 methods. *J Urol* 1992;148:1477.
 63. Merimsky E, Papo J, Zaltzman S, Braf Z. High ligation or embolization of varicocele. *Isr J Med Sci* 1986;22:877-879.
 64. Lenk S, Fahlenkamp D, Gliech V, Lindeke A. Comparison of different methods of treating varicocele. *J Androl* 1994;15:34S-37S.
 65. Dewire DM, Thomas AJ Jr, Flak RM, et al. Clinical outcome and cost comparison of percutaneous embolization and surgical ligation of varicocele. *J Androl* 1994 15(suppl):38-42.
 66. Nieschlag E, Behre M, Schlingheider A, Nashan D, Pohl J, Fishedick AR. Surgical ligation vs. angiographic embolization of the vena spermatica: a prospective randomized study for the treatment of varicocele-related infertility. *Andrologia* 1993;25:233-237.